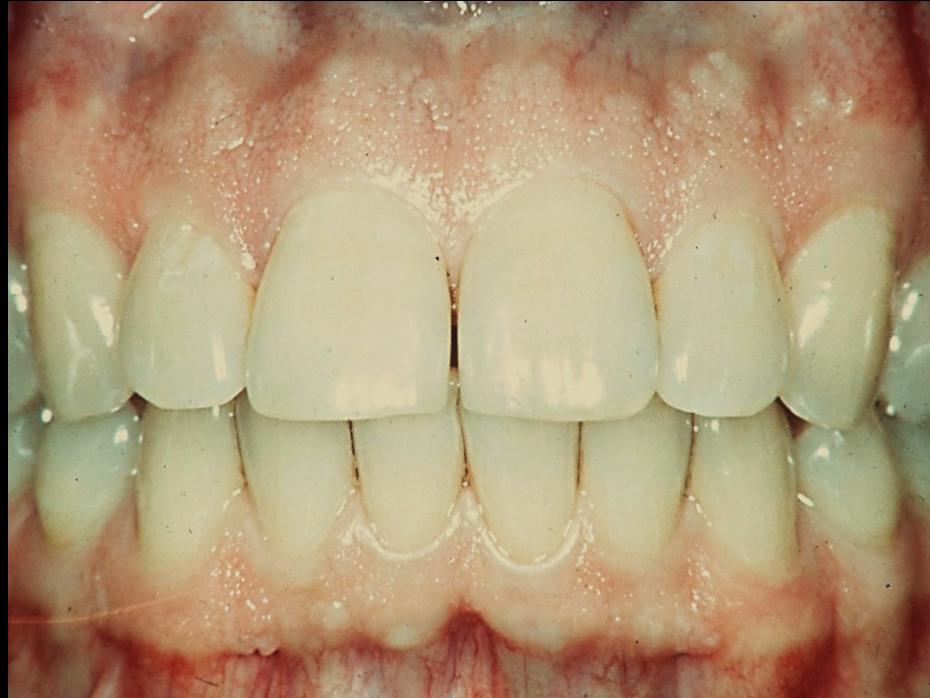
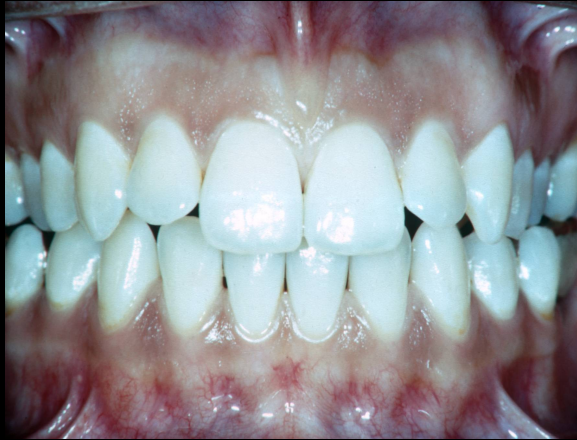
PATRICIA  
SUKMONOWSKI  
DDS

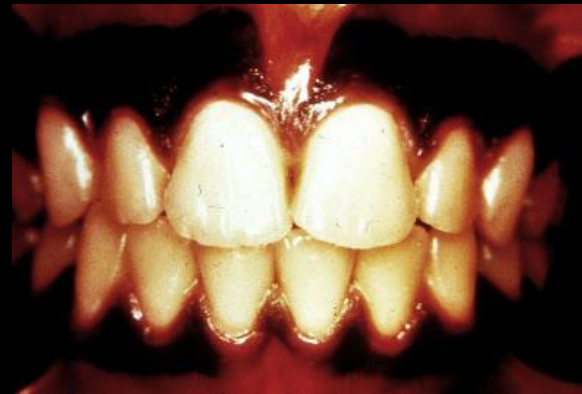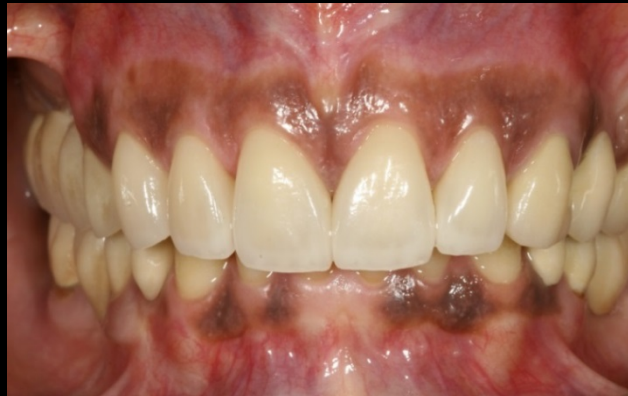PERIODONTAL DISEASE

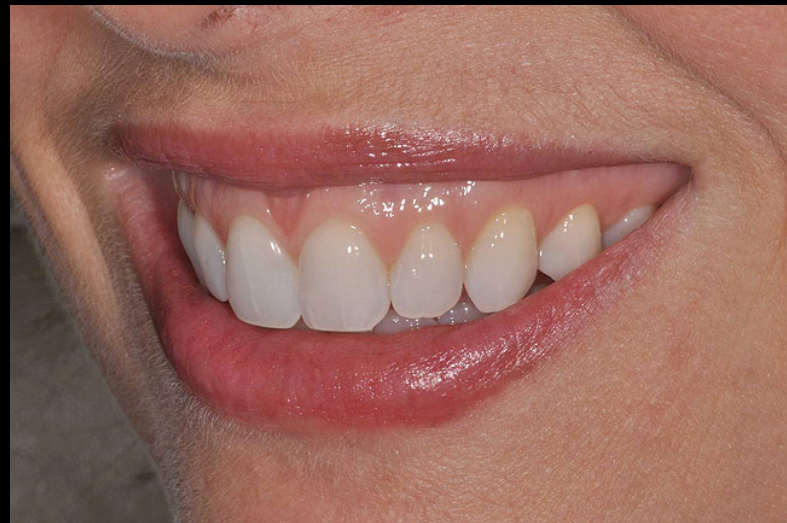
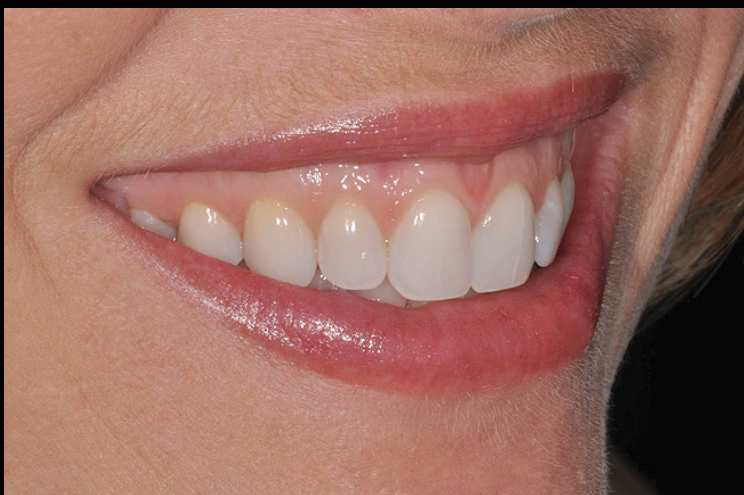
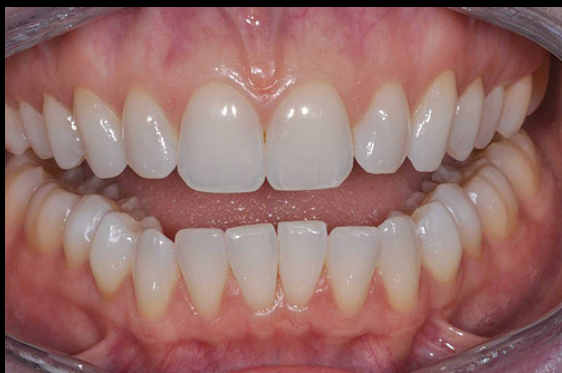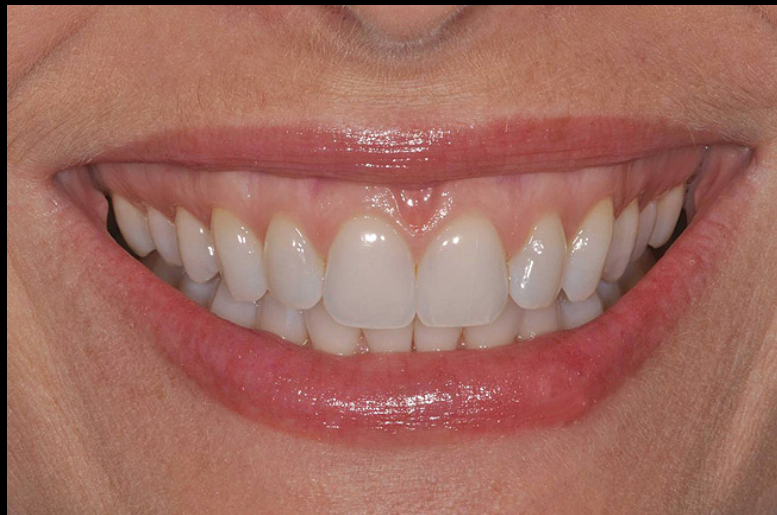Healthy Gums



Healthy Gums with Varying Natural Pigmentation



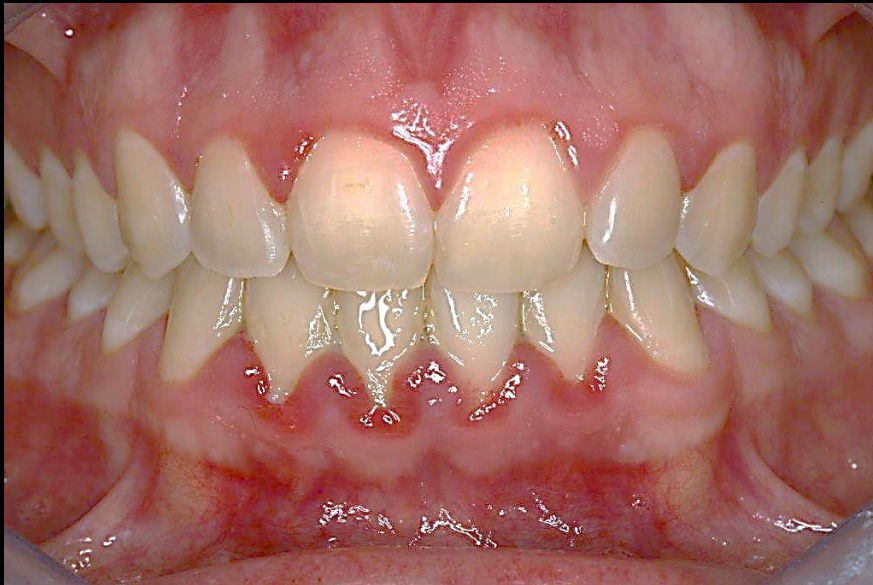

Healthy Gums

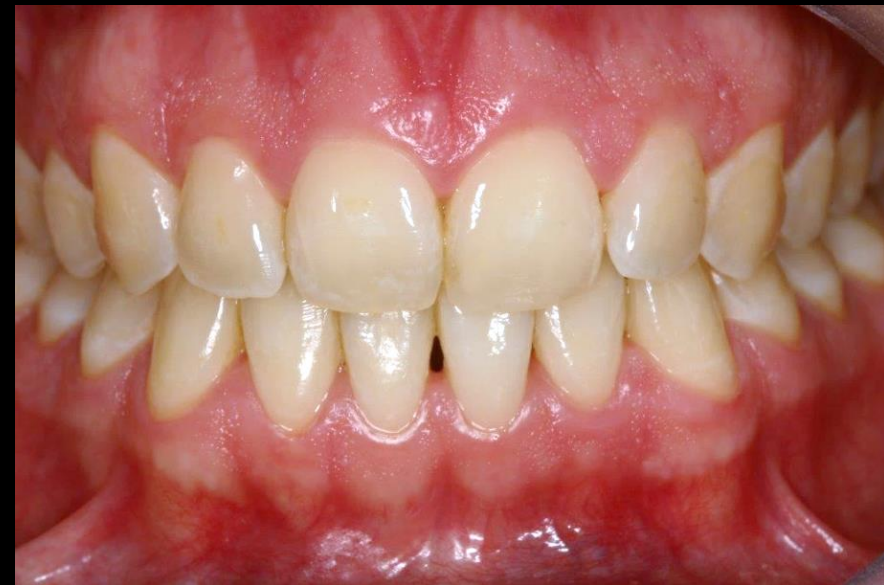

Gingivitis  
Inflammation of the Gums

Case 1



Before

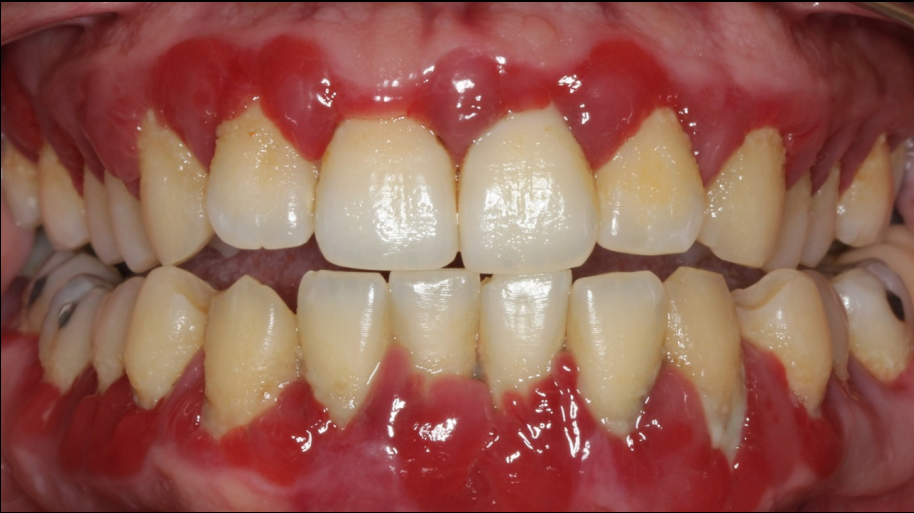

After

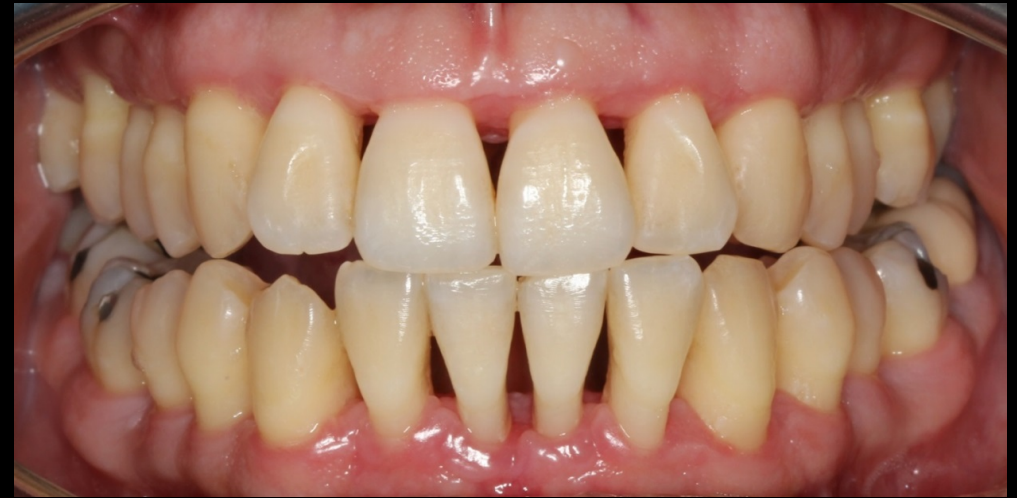Treatment with Scaling and Root Planing

Severe Gingivitis  
Inflammation of the Gums

Case 2



Before

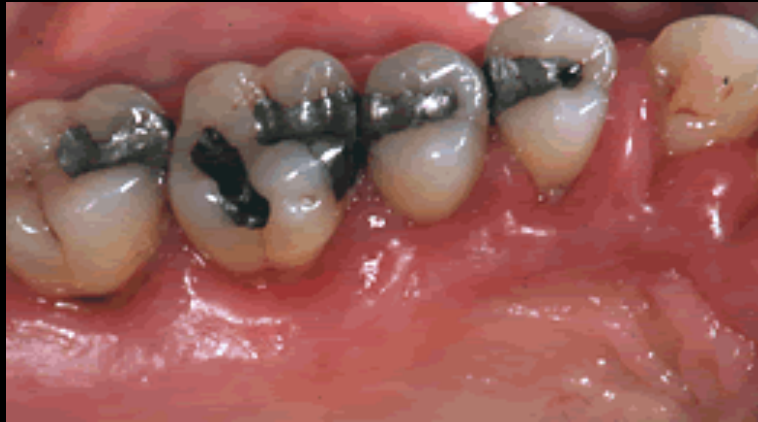

After

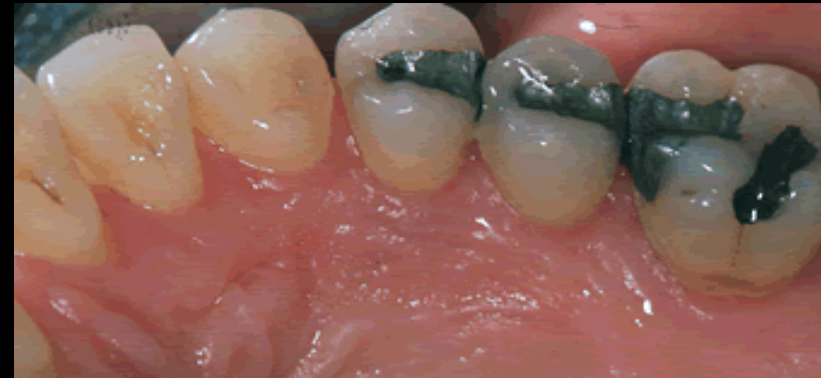Treatment with Scaling and Root Planing

Severe Gingivitis  
Inflammation of the Gums

Case 3



Before

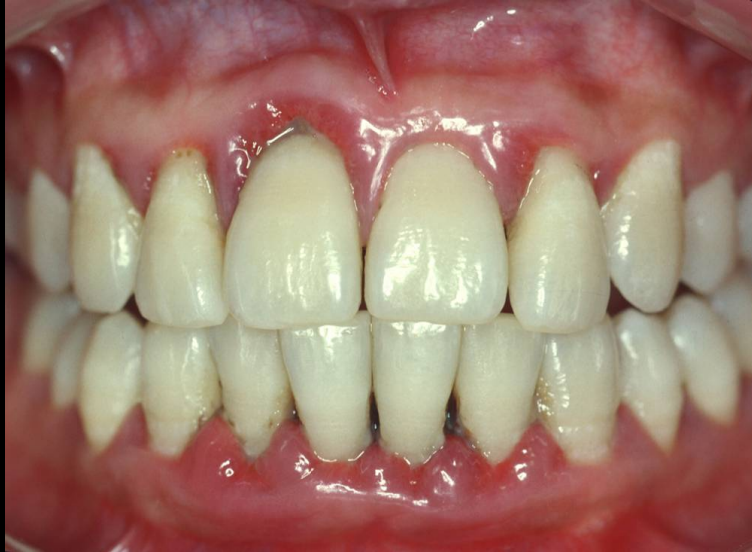

After

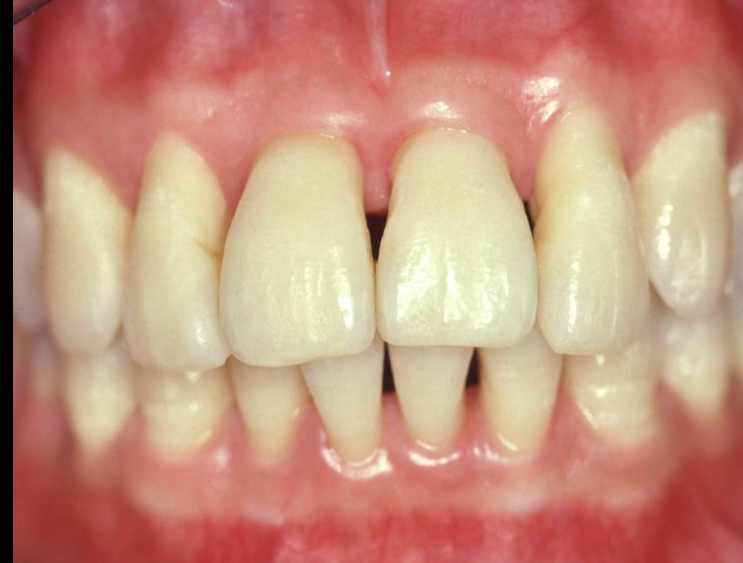Treatment with Scaling and Root Planing

Severe Gingivitis  
Inflammation of the Gums

Case 4



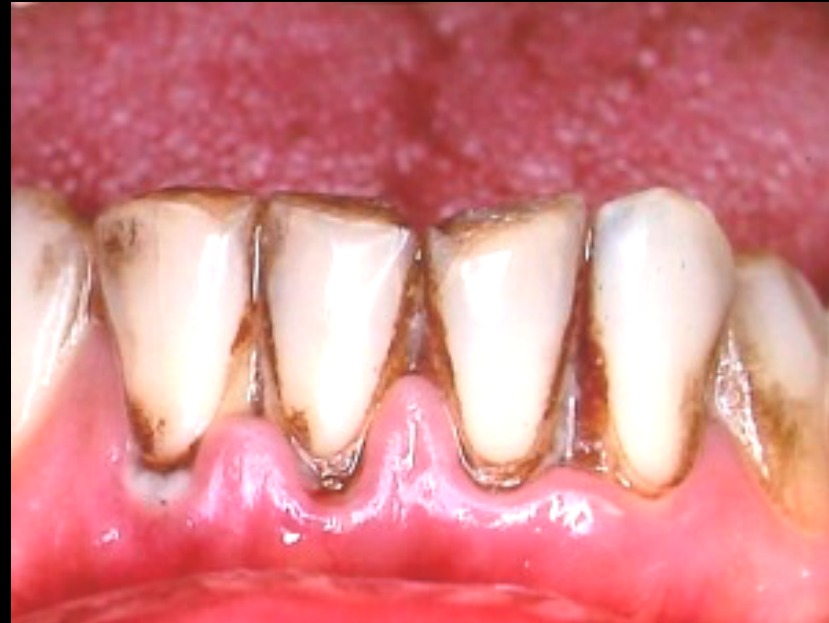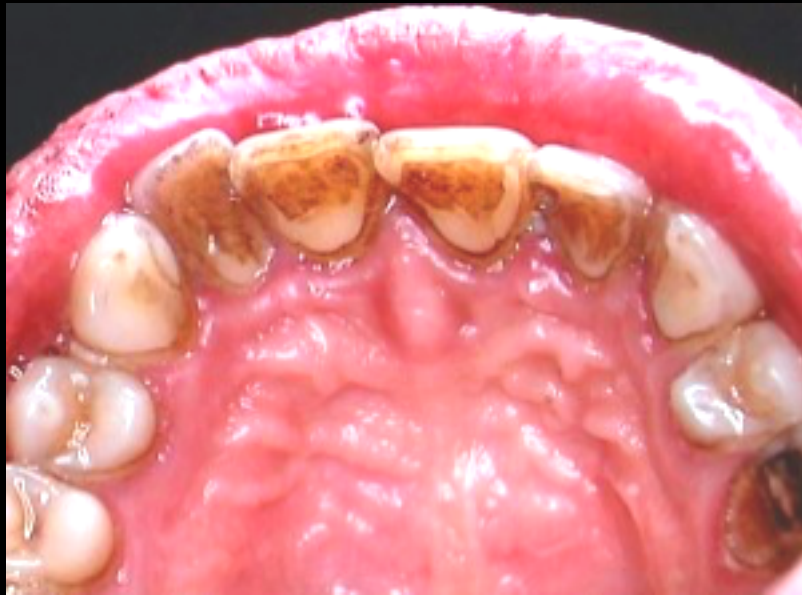Before



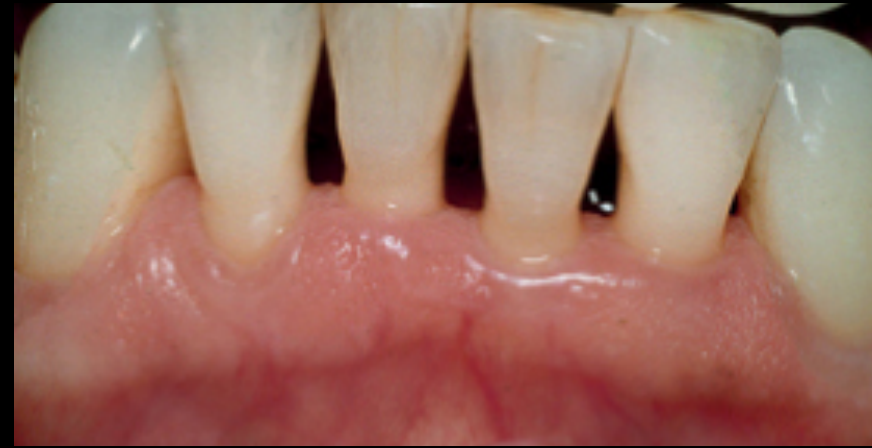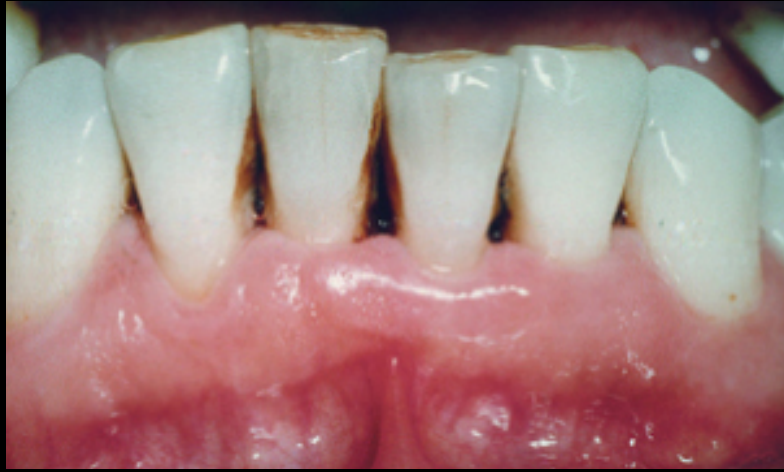After

Treatment with Scaling and Root Planing

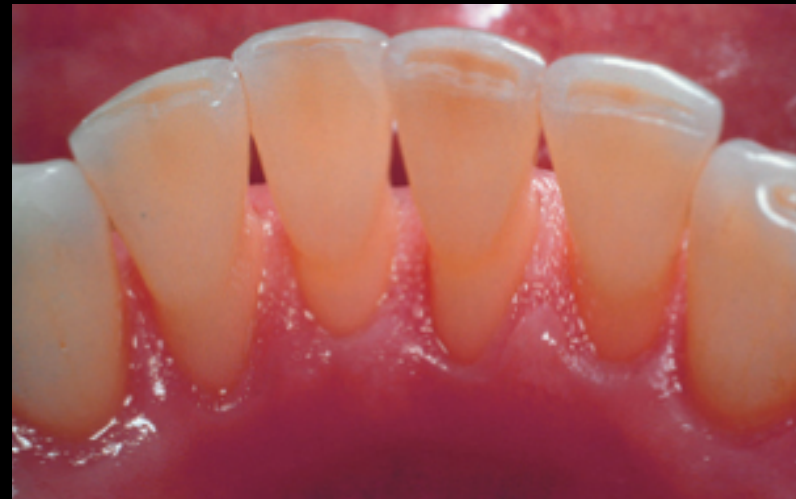
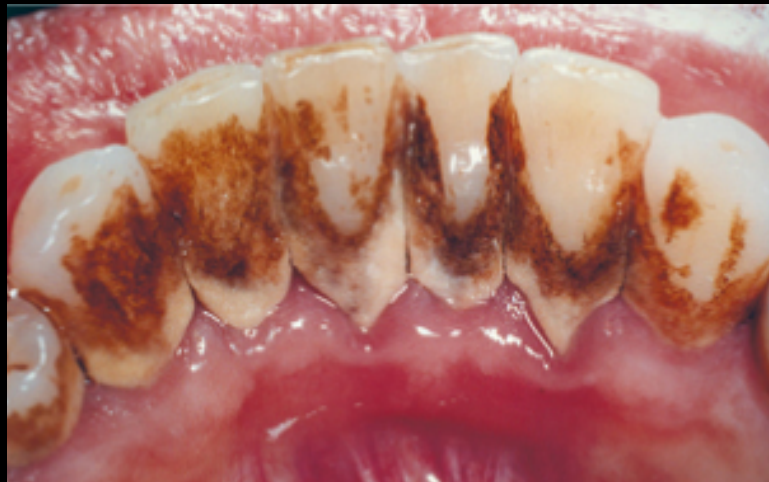


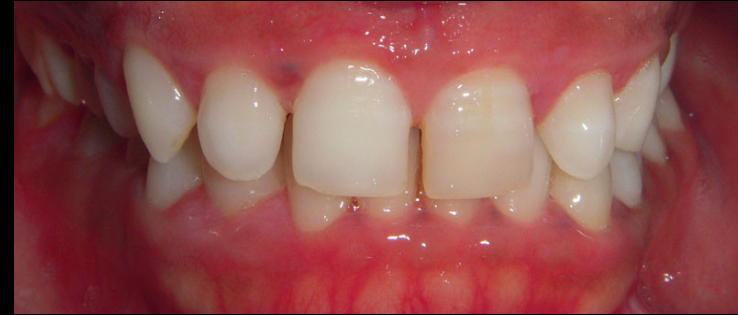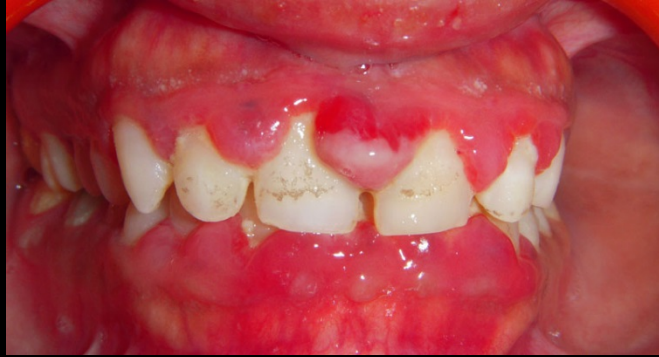Smokers' Mouth



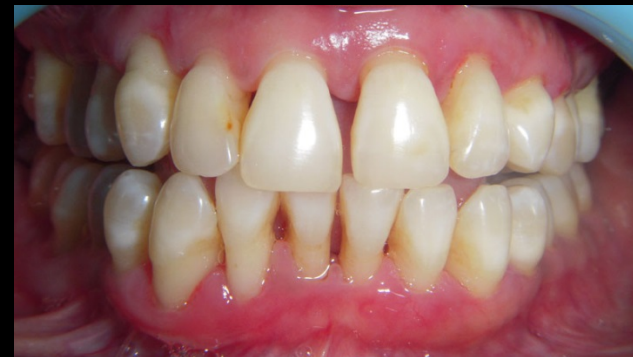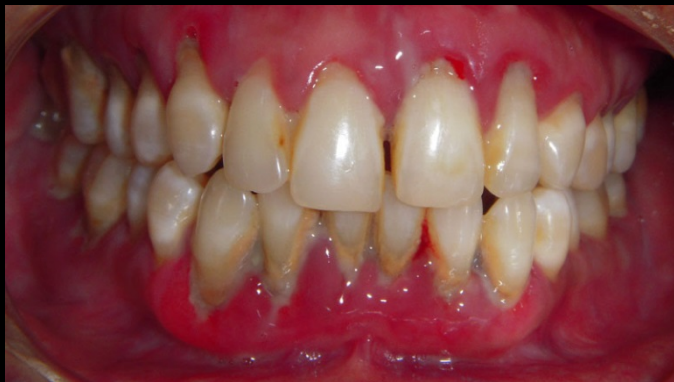Case 5      Smokers' Mouth Before and After Treatment of Scaling and Root Planing





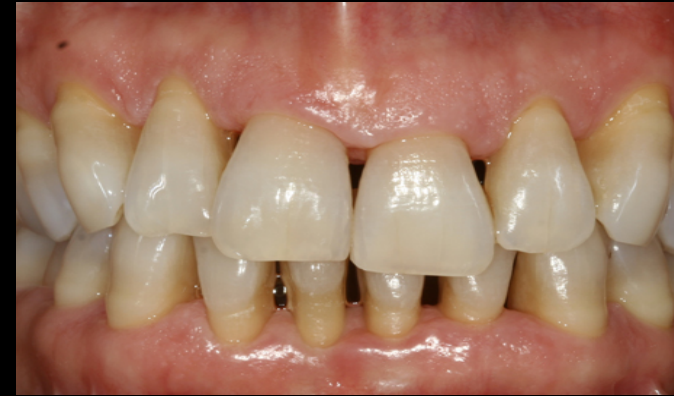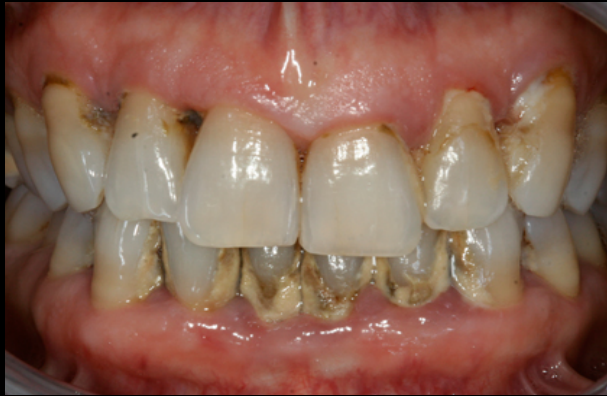### Periodontal Disease with Severe Gingival Inflammation

Before and After Initial Therapy including Non-Surgical removal of plaque, calculus and oral hygiene instruction

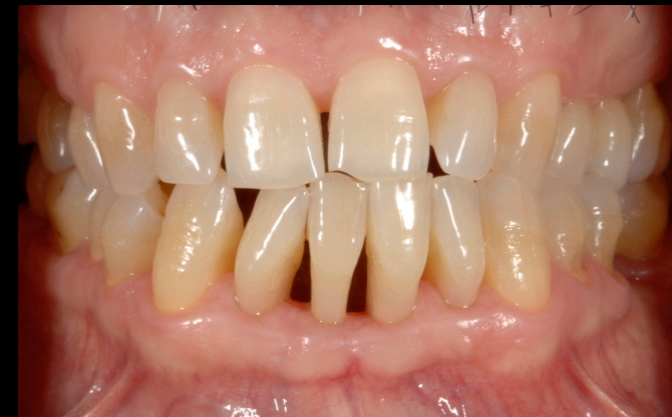
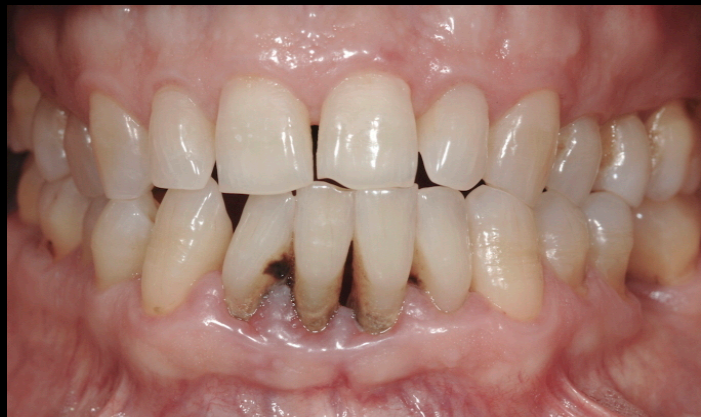


## Periodontal Disease

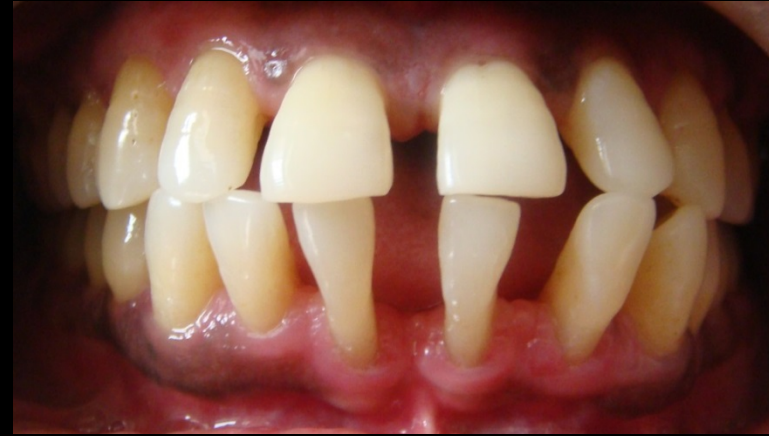
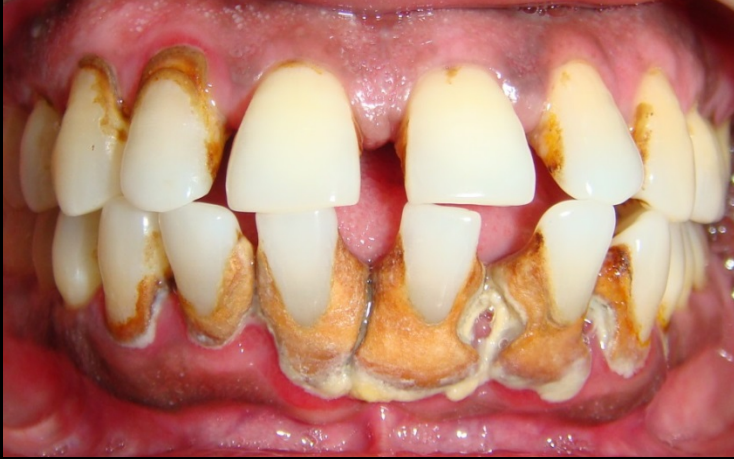
Before and After Initial Therapy including Non-Surgical removal of plaque, calculus and oral hygiene instruction

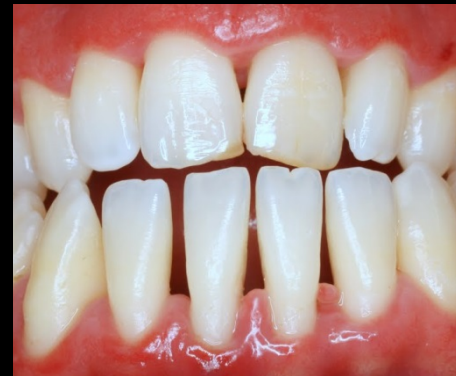
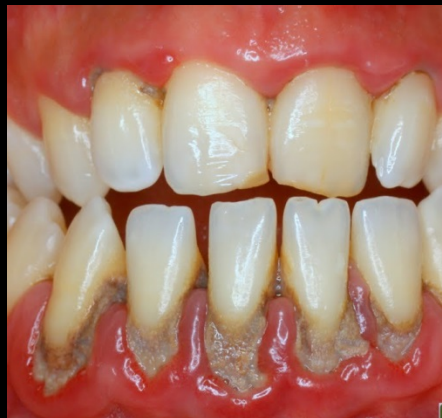


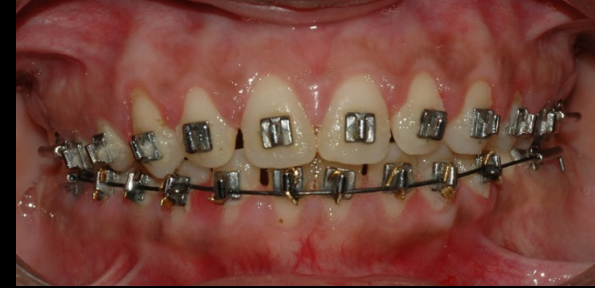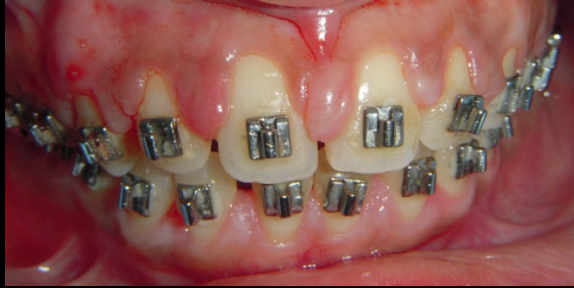## Periodontal Disease



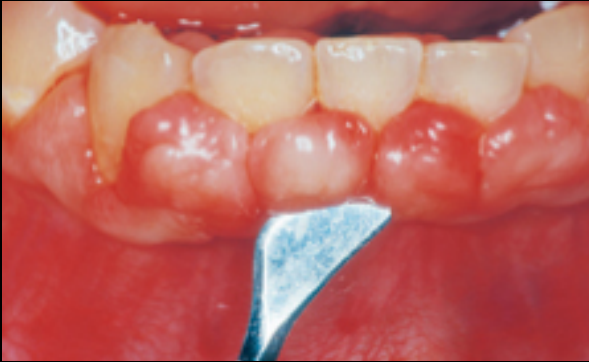Before and After Initial Therapy including Non-Surgical removal of plaque, calculus and oral hygiene instruction



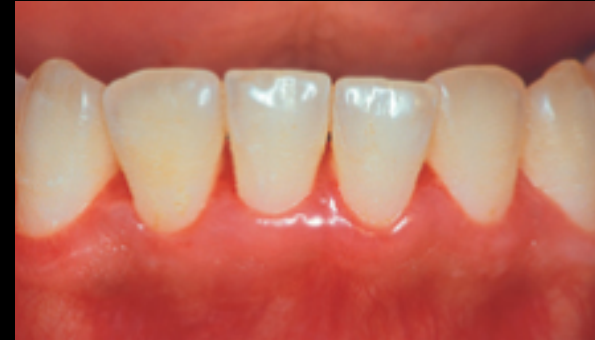

Interdisciplinary treatment requiring periodontal and orthodontic treatment

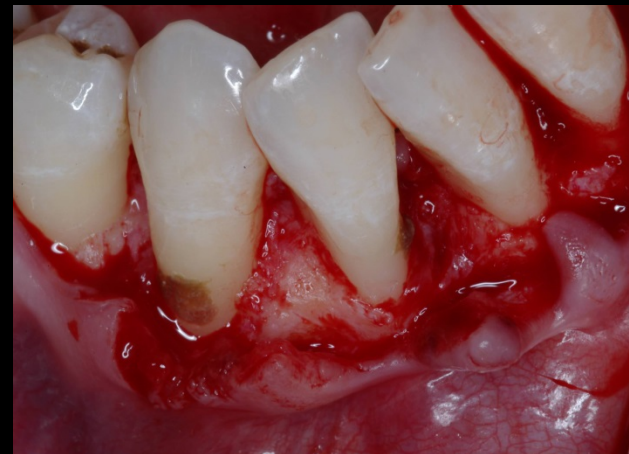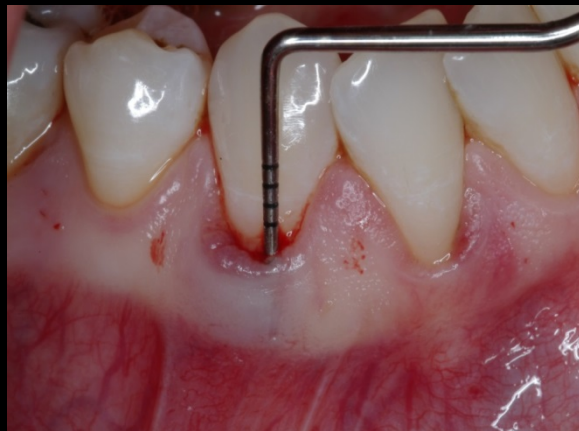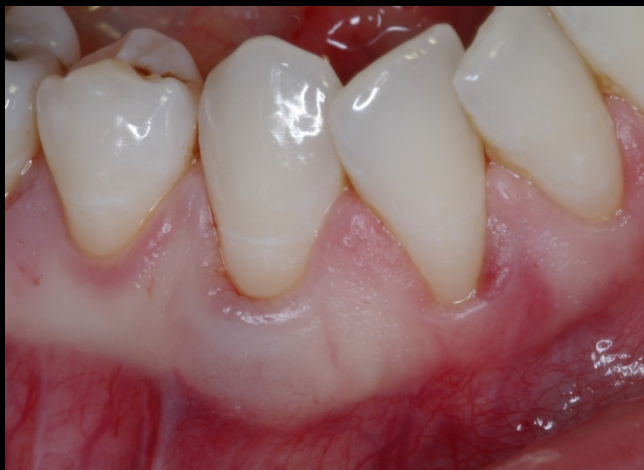## Surgical Correction of Gingival Overgrowth



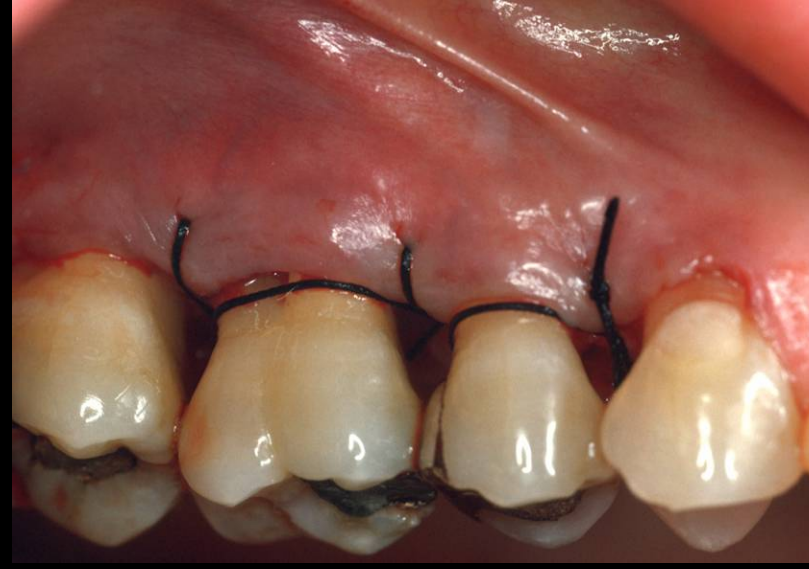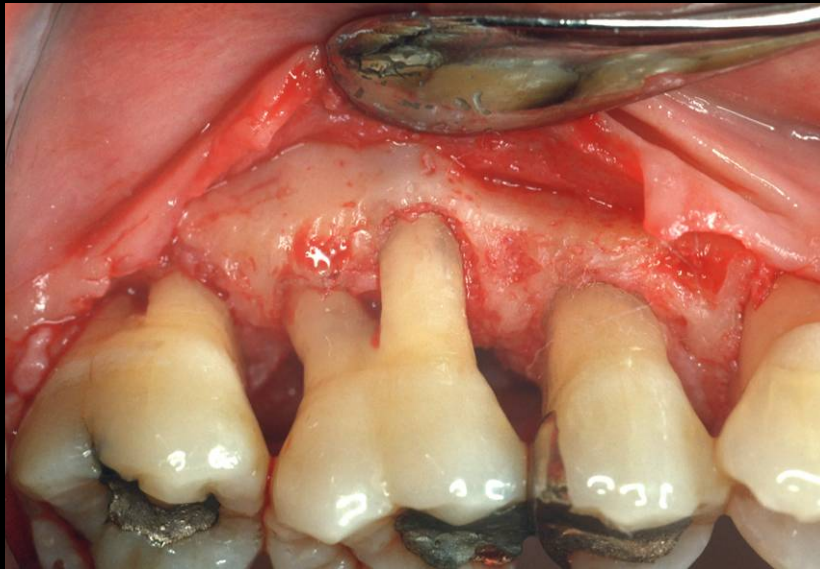
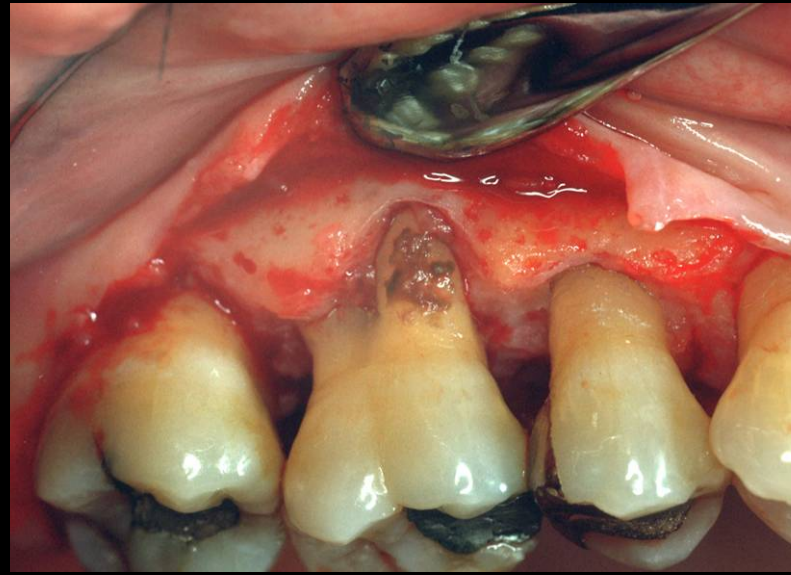
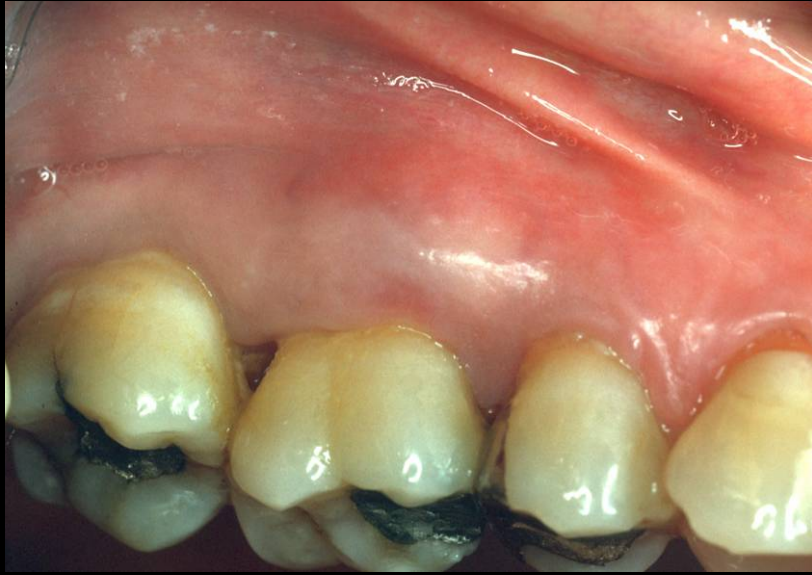Before

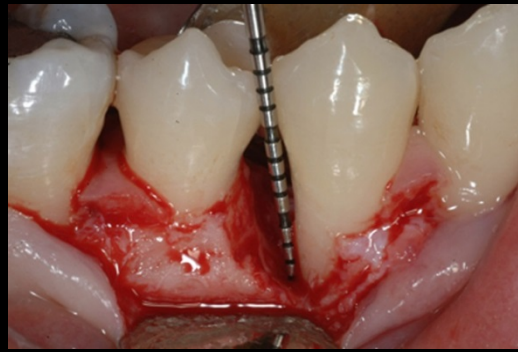
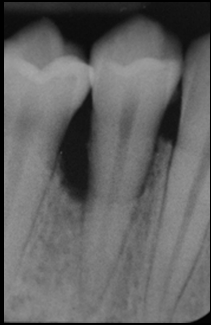
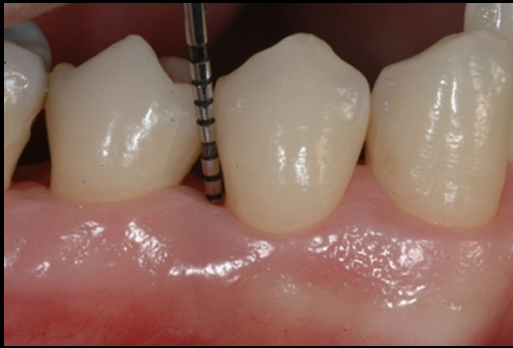After

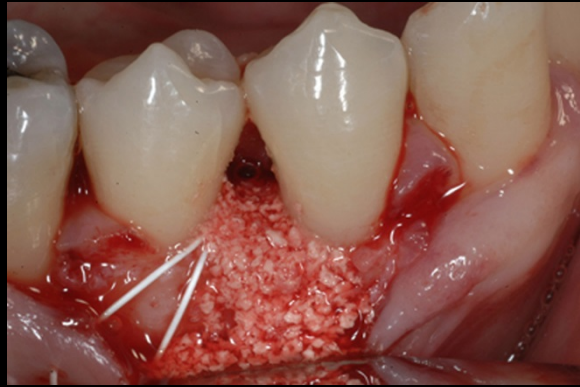








Before



Bone Grafting Procedure with Re-entry

After

