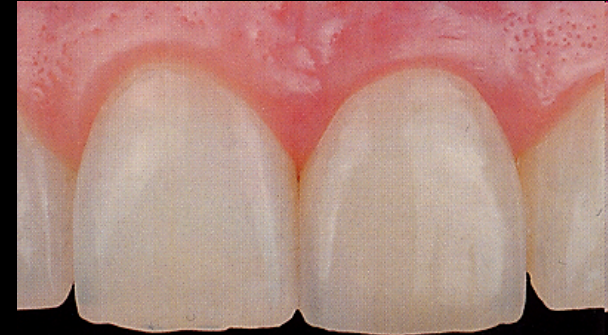
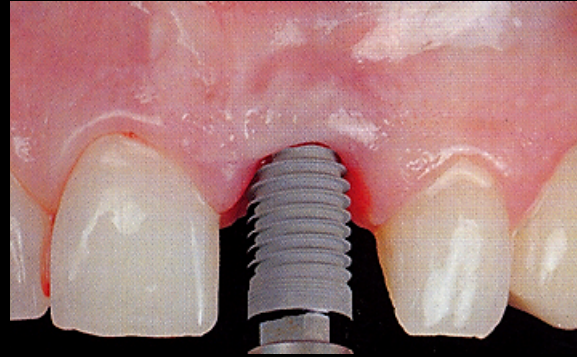
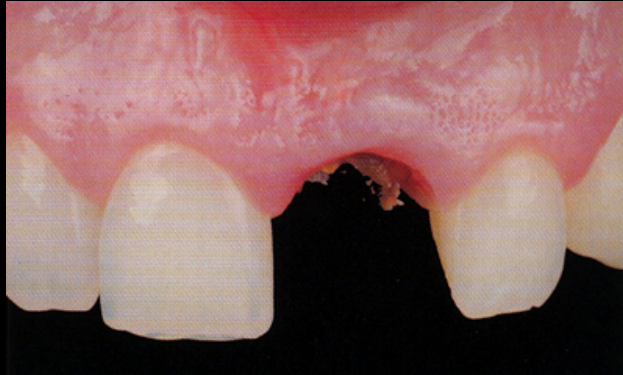


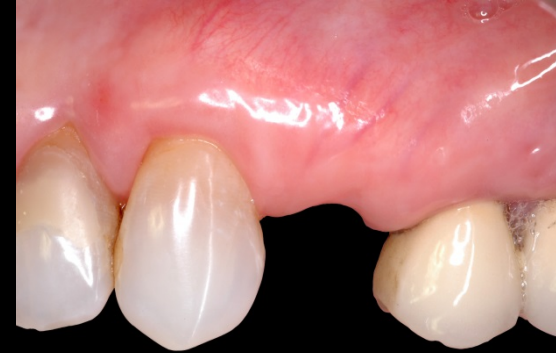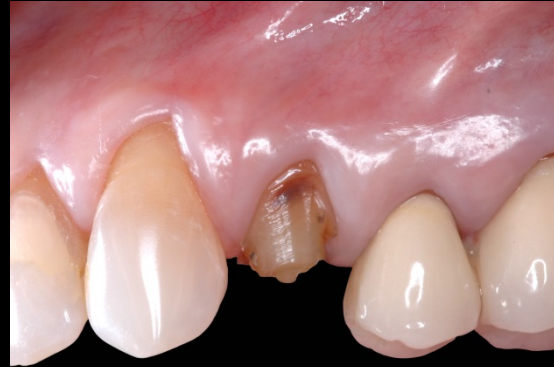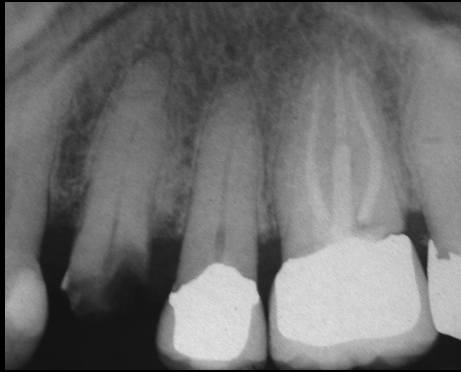
PATRICIA
SUKMONOWSKI
DDS

DENTAL IMPLANTS
SINGLE TOOTH IMPLANT REPLACEMENT



A Decayed, Non Restorable Front Tooth

The Tooth Required Extraction and was Replaced with an Implant



A Fractured Posterior Tooth on a 28 Year Old Woman Replaced with an Implant Crown

