

SYNCHRONIZED RF & HIFEM: UPPER ARMS MRI STUDY

SIMULTANEOUS HIFEM AND SYNCHRONIZED RF PROCEDURE CAN BE EFFECTIVELY USED FOR UPPER ARM TONING AND STRENGTHENING

Carolyn Jacob, M.D.¹, Robert A. Weiss, M.D.²

1. Chicago Cosmetic and Dermatologic Research, Chicago, IL, USA;

2. Maryland Laser Skin and Vein Institute, Hunter Valley, MD, USA.

Accepted at American Society for Laser Medicine and Surgery 2022, San Diego, CA

HIGHLIGHTS

- 34 subjects (23-72 years old, BMI 18.5-33.9 kg/m²) received four 30-minute treatments
- **Fat thickness** was reduced significantly by **25.5%** (0.5±0.1cm) at 3-month follow-up visit.
- The average increase in **triceps muscle thickness** at 3 months was **23.9%** (0.9±0.2cm)
- 87% of patients reported satisfaction with treatment results

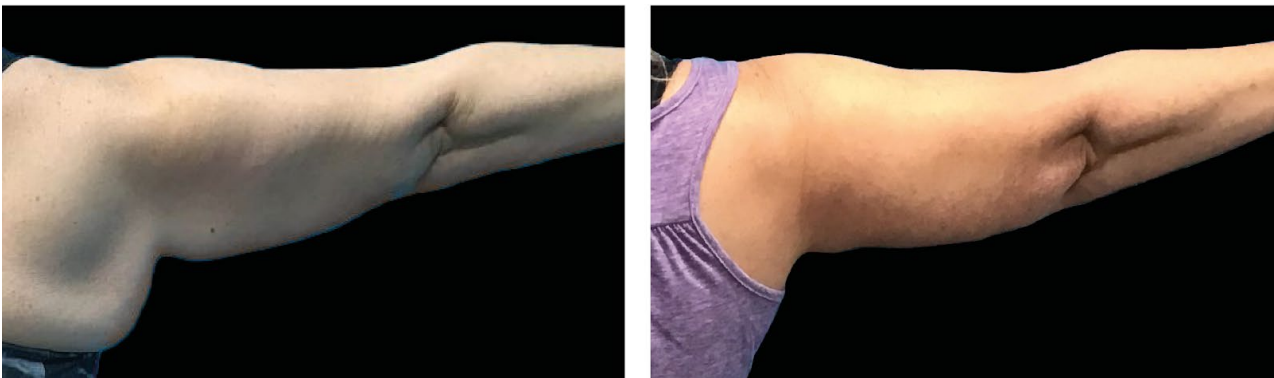

Figure 1: At baseline, the subject showed greater amount of upper arm adiposity, which hung rather loosely. 3-month photographs show upper arm tightening accompanied by marked decrease in arm fat.

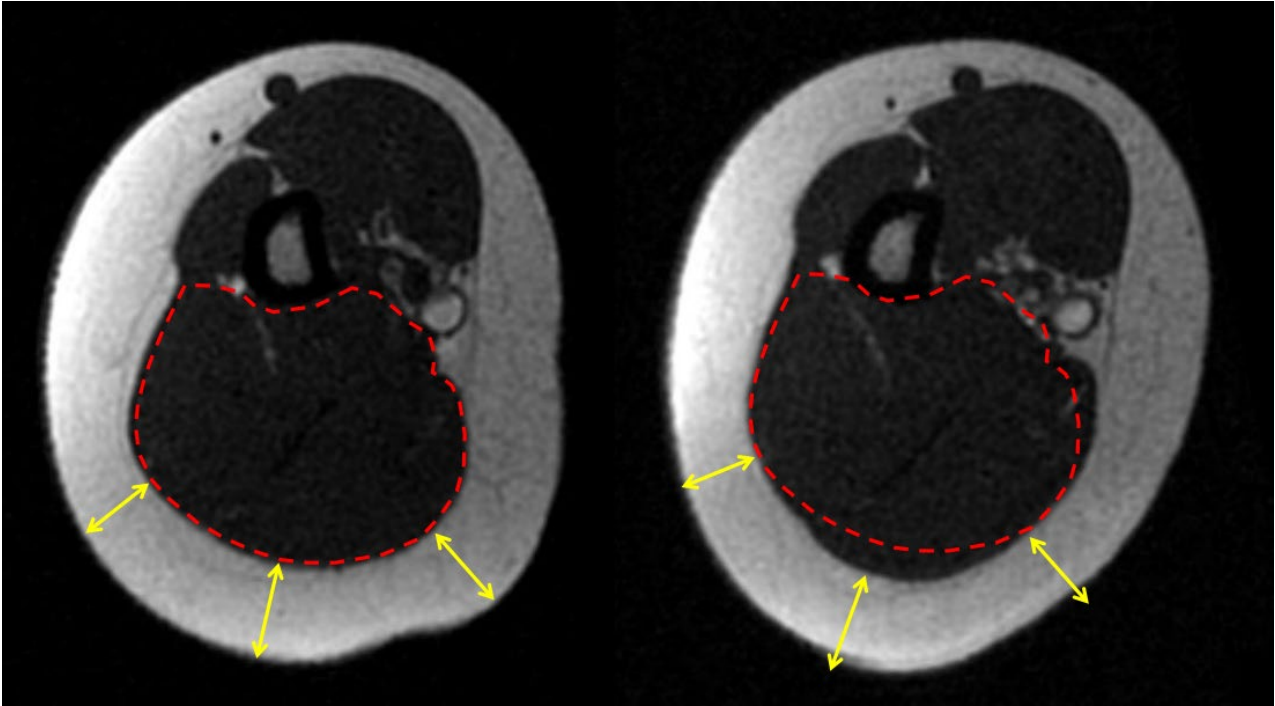


Figure 2: MRI scan showing difference in triceps muscle (red outlined area) and subcutaneous fat layer (yellow arrows) before (left) and 3 months after (right) treatment. The muscle increased in volume noticeably whereas the fat layer thickness reduced.

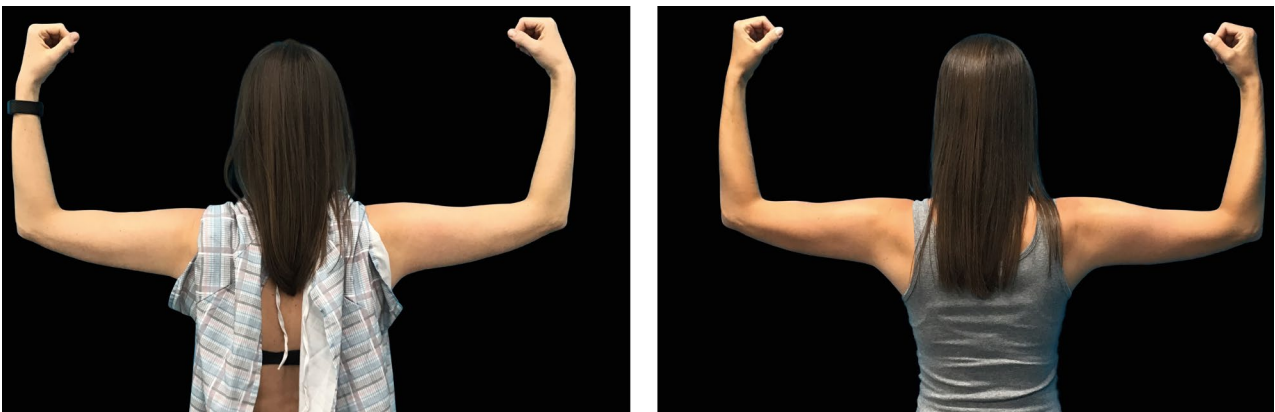

Figure 3: Female at baseline (left) and 3 months after treatment (right). Compared to baseline, this subject shows better triceps muscle definition and improved upper arm tone.